

Canadian Association of Radiologists Cardiovascular Imaging Referral Guideline

Candyce Hamel¹ , Barb Avard², Neil Isaac³, Davinder Jassal⁴,
Iain Kirkpatrick⁵, Jonathon Leipsic⁶, Alan Michaud⁷ ,
James Worrall⁸, and Elsie T. Nguyen⁹ 

Canadian Association of
Radiologists Journal
2024, Vol. 75(4) 721–734
© The Author(s) 2024



Article reuse guidelines:
sagepub.com/journals-permissions
DOI: 10.1177/08465371241246425
journals.sagepub.com/home/caj



Abstract

The Canadian Association of Radiologists (CAR) Cardiovascular Expert Panel is made up of physicians from the disciplines of radiology, cardiology, and emergency medicine, a patient advisor, and an epidemiologist/guideline methodologist. After developing a list of 30 clinical/diagnostic scenarios, a rapid scoping review was undertaken to identify systematically produced referral guidelines that provide recommendations for one or more of these clinical/diagnostic scenarios. Recommendations from 48 guidelines and contextualization criteria in the Grading of Recommendations, Assessment, Development, and Evaluations (GRADE) for guidelines framework were used to develop 125 recommendation statements across the 30 scenarios (27 unique scenarios as 2 scenarios point to the CAR Thoracic Diagnostic Imaging Referral Guideline and the acute pericarditis subscenario is included under 2 main scenarios). This guideline presents the methods of development and the referral recommendations for acute chest pain syndromes, chronic chest pain, cardiovascular screening and risk stratification, pericardial syndromes, intracardiac/pericardial mass, suspected valvular disease cardiomyopathy, aorta, venous thrombosis, and peripheral vascular disease.

Résumé

Le groupe d'experts en radiologie du système cardiovasculaire de l'Association canadienne des radiologistes (CAR) regroupe des radiologistes, des cardiologues, des urgentologues, une représentante des patients et une épidémiologiste spécialisée en méthodologie de l'élaboration de lignes directrices. Après avoir élaboré une liste de 30 scénarios cliniques/diagnostiques, le groupe d'experts a entrepris une revue rapide de délimitation du problème en vue de repérer les lignes directrices relatives aux demandes d'examen produites de façon systématique qui fournissent des recommandations pour un ou plusieurs de ces scénarios. Les recommandations de 48 lignes directrices et critères de contextualisation du cadre GRADE (notation des recommandations, analyses, développements et évaluations) concernant la structure des lignes directrices ont été utilisées pour rédiger 125 énoncés de recommandations couvrant les 30 scénarios (27 de ces scénarios sont uniques; deux se réfèrent aux lignes directrices de la CAR relatives aux demandes d'examen en imagerie diagnostique du thorax et la section concernant la péricardite aiguë est dupliquée pour se retrouver sous deux scénarios principaux). Ces lignes directrices présentent les étapes à suivre et les recommandations de demandes d'examen dans le cas de syndromes de douleur thoracique aiguë,

¹ Canadian Association of Radiologists, Ottawa, ON, Canada

² North York General Hospital, Toronto, ON, Canada

³ Department of Medical Imaging, North York General Hospital, Toronto, ON, Canada

⁴ Section of Cardiology, Department of Internal Medicine, Max Rady College of Medicine, Rady Faculty of Health Sciences University of Manitoba, Bergen Cardiac Care Centre St. Boniface Hospital, Winnipeg, MB, Canada

⁵ Max Rady College of Medicine, University of Manitoba, St. Boniface Hospital, Winnipeg, MB, Canada

⁶ Department of Medicine, University of British Columbia, Vancouver, BC, Canada

⁷ University of Waterloo, Waterloo, ON, Canada

⁸ Department of Emergency Medicine, The Ottawa Hospital, Ottawa, ON, Canada

⁹ University Medical Imaging Toronto, University of Toronto, Toronto General Hospital, Peter Munk Cardiac Centre, Toronto, ON, Canada

Corresponding Author:

Elsie T. Nguyen, University Medical Imaging Toronto, University of Toronto, Toronto General Hospital, Peter Munk Cardiac Centre, 585 University Avenue, Toronto, ON M5G 2N2, Canada.

Email: elsie.nguyen@uhn.ca

de douleurs thoraciques chroniques, de dépistage cardiovasculaire et de stratification du risque, de troubles du péricarde, de masses du cœur ou du péricarde, de valvulopathies présumées, de cardiomyopathies, de problèmes liés à l'aorte, de thromboses veineuses et de maladies vasculaires périphériques.

Keywords

cardiovascular, heart, peripheral vascular disease, diagnostic imaging, referrals, guideline

Introduction

Beginning in February 2023, an Expert Panel (EP) made up of physicians from the disciplines of radiology, cardiology, and emergency medicine, a patient advisor, and an epidemiologist/guideline methodologist met to develop a new set of recommendations specific to referral pathways for cardiovascular conditions. Through discussion (via a virtual meeting) followed by offline communication, the EP developed a list of 30 clinical/diagnostic scenarios to be covered by this guideline. These recommendations are intended primarily for referring clinicians (eg, family physicians, specialty physicians, nurse practitioners); however, they may also be used by radiologists, individuals/patients, and patient representatives.

Our methods describing the guideline development process, including the rapid scoping review to identify the evidence base, has been published in *CMAJ Open*¹ and an editorial to this series of guideline publications is available in *CARJ*.² The application of well-established scoping review and rapid review guidance (JBI,³ Cochrane Handbook,⁴ Cochrane Rapid Review Methods Group⁵) and guideline methodology (ie, Grading of Recommendations Assessment, Development, and Evaluation or GRADE^{6,7}) were used to identify the evidence-base and to guide the Expert Panel in determining the strength and direction of the

recommendations for each clinical scenario (Table 1). The quality of conduct and reporting of the included guidelines identified in the scoping review were evaluated with the AGREE-II checklist,⁸ using a modified scoring system. In instances where guidelines were lacking, expert consensus was used to develop the recommendation. Contextualization to the Canadian health care system was considered for each recommendation, with discussion around the factors found in the Evidence to Decision framework in GRADE for guidelines (eg, balance of desirable and undesirable outcomes, values and preferences, resources implications).⁷

A systematic search for guidelines (with an a priori defined inclusion criteria) was run in Medline and Embase on March 30, 2023. The search was limited to publications from 2018 onward (Supplemental Appendix 1). Supplemental searching included the following national radiology and/or guideline groups: the American College of Radiology, the National Institute for Health and Care Excellence, and the Royal College of Radiologists 8th Edition (2017). Recommendations for each clinical scenario were formulated over one virtual meeting in September 2023. External review and feedback were obtained from radiologists, a nuclear medicine radiologist, and an emergency physician. The full guideline can be found on the CAR website (www.car.ca).

Table 1. Recommendation Text, Symbol, and Interpretation.

Recommendation	AGAINST	FOR
STRONG	<p>Strong, against “we recommend against” (⇓⇓)</p> <ul style="list-style-type: none"> All or almost all informed people would not recommend/choose the course of action and only a small proportion would. 	<p>Strong, for “we recommend” (⇑⇑)</p> <ul style="list-style-type: none"> All or almost all informed people would recommend/choose the course of action and only a small proportion would not. Request discussion if the intervention is not offered.
CONDITIONAL	<p>Conditional, against “we suggest against” (⇓)</p> <ul style="list-style-type: none"> Most informed people would not recommend/choose the course of action, but a substantial number would. This may be conditional upon patient values and preferences, the resources available or the setting in which the intervention will be implemented. 	<p>Conditional, for “we suggest” (⇑)</p> <ul style="list-style-type: none"> Most informed people would recommend/choose the course of action, but a substantial number would not. This may be conditional upon patient values and preferences, the resources available or the setting in which the intervention will be implemented.

Note. Down arrows are red and Up arrows are green when available in colour.

Created using the guidance provided in Andrews et al.⁶

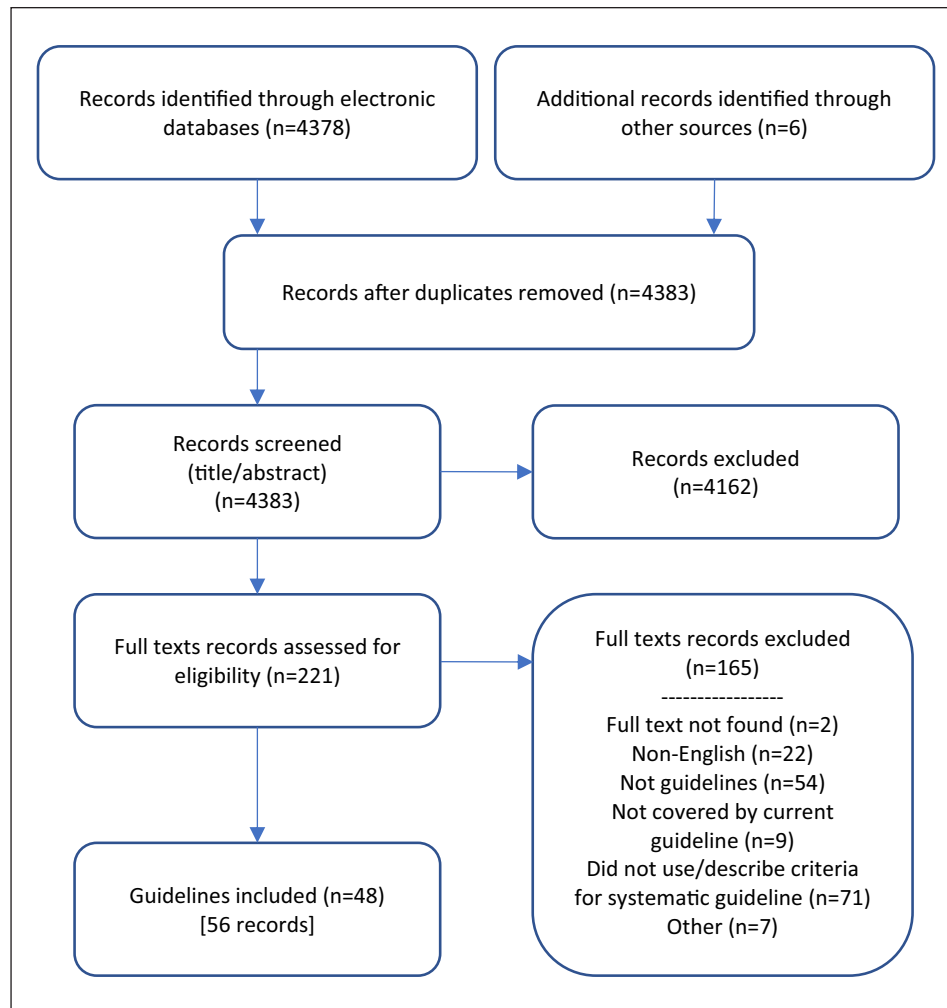


Figure 1. PRISMA flow diagram.

Results

Systematic Scoping Review

A total of 4379 records were identified through the electronic database and 6 additional records were added from the supplemental search. Forty-eight guidelines, plus 8 companion papers, were included (Figure 1). Potentially relevant guidelines published in languages other than English can be found in Supplemental Appendix 2. A list of excluded records with justifications for exclusion is available upon request. Most guidelines were rated as moderate or high quality, using the modified AGREE-II checklist⁸ (Supplemental Appendix 3). The number of guidelines included per clinical/diagnostic scenario ranged from 1 to 10, with a median of 5 guidelines per clinical scenario.

Recommendations

Additional details of the included guidelines, including which imaging modalities (eg, computed tomography [CT],

magnetic resonance imaging [MRI], radiograph [XR], ultrasound [US]) that were discussed can be found in Supplemental Appendix 4.

A guideline is intended to guide and not be an absolute rule. Medical care is complex and should be based on evidence, a clinician's expert judgment, the patient's circumstances, values, preferences, and resource availability. Not all imaging modalities are available in all clinical environments, particularly in rural or remote areas of Canada. Decisions about patient transfer, use of alternative imaging or serial clinical examination and observation can be complex and difficult. Therefore, the expected benefits of recommended imaging, risks of travel, patient preference, and other factors must be considered. The guideline recommendations are designed to assist the choice of imaging modality in situations where it is deemed clinically necessary to obtain imaging.

Recommendations do not always specify when contrast should or should not be used, as this may vary based on clinical presentation, regional practice preferences, preference of

the referring clinician, radiologist and/or the patient, and resource availability. However, where it is essential for diagnosis, the type of imaging that requires contrast is mentioned (e.g., CT pulmonary angiogram, coronary CT angiogram).

We reviewed relevant recommendations related to the 30 clinical/diagnostic scenarios previously published by radiology and specialty societies, including: the Canadian Association of Radiologists,⁹ the American College of Cardiology/American Heart Association (ACC/AHA),¹⁰⁻¹² the American College of Cardiology/American Association for Thoracic Surgery/American Heart Association/American Society of Echocardiography/American Society of Nuclear Cardiology/Heart Rhythm Society/Society for Cardiovascular Angiography and Interventions/Society of Cardiovascular Computed Tomography/Society for Cardiovascular Magnetic Resonance/Society of Thoracic Surgeons (ACC/AATS/AHA/ASE/ASNC/ HRS/SCAI/SCCT/SCMR/STS),^{13,14} the American College of Radiology (ACR),¹⁵⁻²⁶ the American College of Rheumatology/Vasculitis Foundation,^{27,28} the American Heart Association/American College of Cardiology/American Society of Echocardiography/American College of Chest Physicians/Society for Academic Emergency Medicine/Society of Cardiovascular Computed Tomography/Society for Cardiovascular Magnetic Resonance (AHA/ACC/ASE/ACCP/ SAEM/SCCT/SCMR),^{29,30} the American Heart Association/American College of Cardiology (AHA/ACC),^{31,32} the American Heart Association/American College of Cardiology/Heart Failure Society of America

(AHA/ACC/HFSA),^{33,34} the American Society of Hematology (ASH),³⁵ the American Thoracic Society (ATS),³⁶ the Brazil guideline,³⁷ the British Society for Rheumatology (BSR),^{38,39} the Canadian Cardiovascular Society/Canadian Heart Failure Society (CCS/CHFS),⁴⁰ the European Society of Cardiology (ESC),⁴¹⁻⁴⁵ the European League Against Rheumatism (EULAR),⁴⁶⁻⁴⁸ the German Cardiac Society (DGK),⁴⁹ the Italian Society of Vascular and Endovascular Surgery (SICVE),⁵⁰ the Japanese Circulation Society (JCS),^{51,52} the Japanese Circulation Society/Japanese Heart Failure Society (JCS/JHFS),⁵³ the Japanese Circulation Society/Japanese Society for Cardiovascular Surgery/Japanese Association for Thoracic Surgery/Japanese Society for Vascular Surgery (JCS/JSCS/JATS/JSVS),⁵⁴ the National Heart Foundation of Australia/Cardiac Society of Australia and New Zealand (NHFA/CSANZ),⁵⁵ the National Institute for Health and Care Excellence (NICE),⁵⁶⁻⁶⁰ the Royal College of Radiologists (RCR),⁶¹ the Societa Italiana per lo Studio delle Anomalie Vascolari (SISAV),⁶² the Society for Vascular Surgery (SVS),⁶³ and the Thrombosis and Haemostasis Society of Australia and New Zealand (THSANZ).⁶⁴

Recommendations are presented in 3 tables: Acute chest pain syndromes recommendations (Table 2), Chronic chest pain, pericardial syndromes, intracardiac/pericardial mass, and suspected valvular disease recommendations (Table 3), and Cardiomyopathy, aorta, venous thrombosis, and peripheral vascular disease recommendations (Table 4).

Table 2. Acute Chest Pain Syndromes Recommendations.

Clinical/Diagnostic Scenario and Recommendations

CV01. ACUTE CHEST PAIN SYNDROMES

CV01A. Acute coronary syndrome: ST elevation myocardial infarction (STEMI)^{9,13,29,30,33,34,55-57,61}

In patients presenting with suspected acute coronary syndrome, imaging should be offered based on clinical results (ie, ECG and cardiac troponin).

- I. In patients meeting criteria for STEMI (ie, ECG), we recommend **invasive coronary angiography** as the initial imaging modality (↑↑).
 - ↳ I.1 In cases of diagnostic uncertainty OR if immediate invasive coronary angiography is unavailable, we suggest **chest XR and bedside TTE/POCUS (if available)** to evaluate for other potential causes of chest pain, but this should not delay care (↑).
-

CV01B. Acute coronary syndrome: non-STEMI^{9,13,29,30,41,51,56,57,61}

In patients presenting with suspected acute coronary syndrome, imaging should be offered based on clinical results (ie, ECG and cardiac troponin).

- I. In patients with suspected non-STEMI, we recommend **chest XR** (to rule out other causes of chest pain) **and bedside TTE/POCUS** (if available, to evaluate for ventricular function and rule out pericardial effusion) as the initial imaging modalities (↑↑).
 - ↳ I.1 In higher-risk patients, we recommend **invasive coronary angiography** as the next imaging modality (↑↑).
 - ↳ I.2 In lower-risk patients, we recommend **invasive coronary angiography or CCTA** as the next imaging modality, depending on clinical parameters (↑↑).
-

(continued)

Table 2. (continued)

Clinical/Diagnostic Scenario and Recommendations

CV01C. Acute coronary syndrome: unstable angina^{9,13,29,30,56,57,61}

In patients presenting with suspected acute coronary syndrome, imaging should be offered based on clinical results (ie, ECG and cardiac troponin).

1. In patients with suspected unstable angina (ie, negative cardiac troponin), we recommend **chest XR** (to rule out other causes of chest pain) **and bedside TTE/POCUS** (if available, to evaluate for ventricular function and rule out pericardial effusion) as the initial imaging modalities (↑↑).
 - ↳ **1.1** For assessment of coronary artery disease and for risk stratification, we recommend **CCTA** (↑↑).
Depending on regional practice preference and availability, stress echocardiography and NM (stress perfusion) may be considered. Internal medicine/cardiology consultation may also be considered.
 2. In patients with suspected unstable angina with ongoing chest pain not relieved with medical management, we recommend **invasive coronary angiography** (↑↑).
-

CV01D. Acute aortic syndrome (including aortic dissection, intramural haematoma, and penetrating atherosclerotic ulcer)^{9,10,13,15,29,30,61}

1. For patients with suspected acute aortic syndrome, we recommend **CTA** (preferably cardiac-gated, if available) as the initial imaging modality (↑↑).
 - ↳ **1.1** If CTA is contraindicated, we recommend **TEE or MRA** as alternative imaging modalities (↑↑).
-

CV01E. Pulmonary embolism^{9,13,16,29,30,35,42,58,61}

Acute pulmonary embolism

1. In patients with suspected pulmonary embolism with low or intermediate pretest probability (as determined by a structured risk assessment tool) with a negative D-dimer, we recommend **against CTA/MRA/VQ scan** (↓↓).
2. In patients with suspected pulmonary embolism with low or intermediate pretest probability (as determined by a structured risk assessment tool) with a positive D-dimer test, we recommend **CT pulmonary angiography (CTPA)** as the initial imaging modality (↑↑).
 - ↳ **2.1** If immediate CTPA is not available, we recommend **chest XR** as the next imaging modality to exclude other causes of chest pain (↑↑).
 - ↳ **2.2** If CT pulmonary angiography is contraindicated, we suggest **VQ scan or MR pulmonary angiography** as an alternative (↑). [see recommendation 4 for pregnant patients]
3. In patients with suspected pulmonary embolism and high pretest probability (as determined by a structured risk assessment tool) or in patients with recurrent pulmonary embolism, we recommend **CTPA** as the initial imaging modality (↑↑).
 - ↳ **3.1** If immediate CTPA is not available, we recommend **chest XR** as the next imaging modality to exclude other causes of chest pain (↑↑).
 - ↳ **3.2** If CT pulmonary angiography is contraindicated, we suggest **VQ scan or MR pulmonary angiography** as an alternative (↑). [see recommendation 4 for pregnant patients]
4. For pregnant patients with high pretest probability (as determined by a structured risk assessment tool) of pulmonary embolism, we recommend **chest XR** as the initial imaging modality (↑↑).
 - ↳ **4.1** If chest XR does not explain the clinical presentation and further imaging is required, we recommend **Doppler US** as the next imaging modality (↑↑).
 - ↳ **4.2** If Doppler US is negative, we recommend **CTPA or NM (VQ scan)** as the next imaging modality (↑↑).
In pregnant patients with a high pre-test probability of pulmonary embolism, and normal leg dopplers, some guidelines suggest performing V/Q scan. In practice, however, its availability is limited. CTPA is widely available, has better interobserver agreement, and ability to provide alternative diagnoses for acute chest pain presentation that support its use for evaluation of acute pulmonary embolism in pregnant patients. Mean maternal and foetal radiation dose is typically lower for reduced dose NM perfusion scanning (ie, no ventilation scanning performed) and breast radiation dose is typically higher with CTPA.

Note: MRI is not recommended for evaluation of pulmonary embolism in pregnant patients because gadolinium should be avoided in pregnant patients.⁶⁵

Chronic pulmonary embolism

5. In patients with pulmonary hypertension suspected to be secondary to chronic thromboembolic disease (CTEPH), we recommend **VQ scan** as the initial imaging modality (EP consensus).
 - ↳ **5.1** If VQ scan is non-diagnostic, indeterminate for chronic pulmonary embolism, or unavailable, we recommend **CTPA** as an alternative (EP consensus).
Dual energy CT technology or iodine subtraction maps can increase CTPA sensitivity to detect chronic pulmonary embolism.
-

(continued)

Table 2. (continued)

Clinical/Diagnostic Scenario and Recommendations

CV01F. Acute myocarditis^{17,29,30,61}

- I. In patients with suspected acute myocarditis, we recommend **TTE followed by cardiac MRI** as the initial imaging modalities (↑↑).
 - ↳ **I.1** If cardiac MRI does not demonstrate acute myocarditis and if invasive coronary angiography has not been performed, we suggest **CCTA** as the next imaging modality to exclude obstructive coronary artery disease (↑) in appropriately selected patients.

CV01G. Acute pericarditis^{9,17,18,29,30,61}

- I. In patients with suspected acute pericarditis, we recommend **bedside TTE/POCUS or TEE** as the initial imaging modality to assess presence of pericardial thickening, effusion, as well as ventricular function and constrictive physiology (↑↑).
 - ↳ **I.1** If further imaging is required to guide management (ie, pericardiocentesis), we suggest **CT** (preferably cardiac-gated, if available) as the next imaging modality (↑).
 - ↳ **I.2** If TTE is inconclusive regarding acute pericarditis or constrictive physiology, we suggest **cardiac MRI** as an alternative (↑).

CV01H. Non-cardiac chest pain

See the scenarios in the CAR Thoracic Diagnostic Imaging Referral Guideline⁶⁶:

- TH02. Non-specific chest pain
- TH14. Suspected pneumothorax (non-traumatic)
- TH15. Clinically suspected pleural effusion

Note. Strength of recommendation: ↑↑ = strong for; ↑ = conditional for; ↓ = conditional against; ↓↓ = strong against. EP = Expert Panel; CCTA = coronary computed tomography angiography; CT = computed tomography; CTA = computed tomography angiography; CTPA = computed tomography pulmonary angiography; ECG = electrocardiography; MR = magnetic resonance; MRA = magnetic resonance angiography; MRI = magnetic resonance imaging; NM = nuclear medicine; POCUS = point of care ultrasound; STEMI = ST elevation myocardial infarction; TEE = transesophageal echocardiograph; TTE = transthoracic electrocardiograph; VQ scan = ventilation/perfusion scan; US = ultrasound; XR = radiograph.

Table 3. Chronic Chest Pain, Pericardial Syndromes, Intracardiac/Pericardial Mass, and Suspected Valvular Disease Recommendations.

Clinical/Diagnostic Scenario and Recommendations

CV02. CHRONIC CHEST PAIN**CV02A. Suspected chronic ischaemic heart disease**^{9,13,19,29,30,33,34,43,44,51,55,61}

- I. In patients *with established chronic ischaemic heart disease* with recurrent chest pain symptoms despite guideline directed medical therapy and intermediate risk/pre-test probability or known non-obstructive CAD, we suggest **anatomical (CCTA), functional (stress NM, stress echo) imaging, or stress MR** as the initial imaging modalities (↑).
 - ↳ **I.1** To identify patients who may benefit from further investigation with invasive coronary angiography, we suggest **CT-fractional flow reserve (CT-FFR)** (↑).
2. In patients *with established chronic ischaemic heart disease* with recurrent chest pain symptoms despite guideline directed medical therapy and high risk/pre-test probability, we recommend **invasive coronary angiography** as the initial imaging modality (↑↑).
3. In patients *with established chronic ischaemic heart disease* with prior coronary revascularization with percutaneous coronary intervention (PCI) or coronary artery bypass grafts (CABG) and with recurrent chest pain symptoms, we suggest **CCTA** to evaluate for stent (especially if stent > 3mm) or graft patency (↑).
 - ↳ **3.1** If evaluation for ischaemia to account for symptoms is important, we recommend **NM (myocardial perfusion scan)** (↑↑).
4. In patients with stable chest pain *without established ischaemic heart disease* presenting to the outpatient clinic and at low risk/pre-test likelihood of having obstructive CAD (as determined by a structured assessment tool), **routine imaging investigations** are not recommended (↓↓).
 - ↳ **4.1** In selected patient populations, we suggest **calcium score CT** (for excluding calcified plaque and identifying patients at low likelihood of obstructive CAD) or **exercise ECG testing** (↑).
5. In patients *without established chronic ischaemic heart disease* with recurrent stable chest pain symptoms and intermediate or high risk/pre-test probability, we recommend **CCTA** for diagnosis of CAD, risk prognostication and guiding of treatment decisions (↑↑).
 - ↳ **5.1** For diagnosis of myocardial ischaemia and estimation of risk of major adverse cardiovascular events (MACE), we recommend **functional imaging (stress echocardiography or PET/SPECT MPI or CMR)** (↑↑).

(continued)

Table 3. (continued)

Clinical/Diagnostic Scenario and Recommendations

CV02B. Non-cardiac chest pain

See the scenarios in the CAR Thoracic Diagnostic Imaging Referral Guideline⁶⁶:

- TH02. Non-specific chest pain
 - TH15. Clinically suspected pleural effusion
-

CV03. cardiovascular screening and risk stratification (calcium score CT)⁶¹

1. In asymptomatic low-risk adults, we suggest **against routine cardiovascular imaging screening and risk stratification** (↓).
2. In asymptomatic intermediate-risk adults, we recommend **calcium score CT** for optimal risk stratification to guide medical management (↑↑).

In high-risk patients reluctant to initiate optimal medical management, calcium score CT can provide useful information for patient counselling.

CV04. Pericardial syndromes**CV04A. Acute pericarditis**

See CV01G. Acute chest pain syndromes: Acute pericarditis in Table 2.

CV04B. Pericardial effusion^{9,13,61}

1. In patients with suspected pericardial effusion, we recommend **TTE** as the initial imaging modality (↑↑).
 - ↳ **1.1** If there is suspected effusive constrictive/constrictive physiology, we suggest **CT** (preferably cardiac-gated, if available) as the next imaging modality to evaluate for pericardial thickness, pericardial effusion, and calcification (↑).
 - ↳ **1.2** If TTE is inconclusive for effusive constrictive/constrictive physiology, we recommend **cardiac MRI** as the next imaging modality (↑↑).
 - ↳ **1.3** If cardiac MRI is inconclusive for effusive constrictive/constrictive physiology, we recommend **cardiac catheterization** (↑↑).
-

CV04C. Constrictive pericarditis^{13,61}

1. In patients with suspected constrictive pericarditis, we recommend **TTE** as the initial imaging modality (↑↑).
 - ↳ **1.1** If there is suspected constrictive physiology, we suggest **CT** (preferably cardiac-gated, if available) as the next imaging modality to evaluate for pericardial thickness and calcification (↑).
 - ↳ **1.2** If TTE is inconclusive for constrictive physiology, we recommend **cardiac MRI** as the next imaging modality (↑↑).
 - ↳ **1.3** If cardiac MRI is inconclusive for constrictive physiology, we recommend **cardiac catheterization** (↑↑).
-

CV05. Intracardiac/pericardial mass**CV05A. Normal variant¹³**

1. In patients with a suspected intracardiac or pericardial mass (versus normal variant) detected on chest CT, we recommend **TTE** as the initial imaging modality (↑↑).
 - ↳ **1.1** If further imaging is required, we recommend **cardiac MRI** as the next imaging modality (↑↑).
 - ↳ **1.2** If cardiac MRI is not tolerated, is unavailable, or is contraindicated, we recommend **cardiac CT** as an alternative imaging modality (↑↑).
 2. In patients with a suspected intracardiac or pericardial mass (versus normal variant) incidentally detected on TTE, we recommend **cardiac MRI** for further characterization (↑↑).
 - ↳ **2.1** If cardiac MRI is not tolerated, is unavailable, or is contraindicated, we recommend **cardiac CT** as the next imaging modality (↑↑).
-

CV05B. Masses¹³

1. In patients with intracardiac or pericardial mass detected on chest CT, we recommend **TTE** as the initial imaging modality (↑↑).
 - ↳ **1.1** If further imaging is required, we recommend **cardiac MRI** as the next imaging modality (↑↑).
 - ↳ **1.2** If cardiac MRI is not tolerated, is unavailable, or is contraindicated, we recommend **cardiac CT** as an alternative imaging modality (↑↑).
2. In patients with intracardiac or pericardial mass detected on TTE, we recommend **cardiac MRI** for further characterization (↑↑).
 - ↳ **2.1** If cardiac MRI is not tolerated, is unavailable, or is contraindicated, we recommend **cardiac CT** as the next imaging modality (↑↑).

Cardiac PET may be helpful to guide management.

(continued)

Table 3. (continued)

Clinical/Diagnostic Scenario and Recommendations

CV06. Suspected valvular disease

CV06A. Aortic valve^{9,11-14,18,20,54,61}

Aortic stenosis

1. In patients with suspected aortic valve stenosis, we recommend **TTE** as the initial imaging modality (↑↑).
 - ↳ 1.1 If the severity of the aortic valve stenosis is unclear (eg, in suspected low flow low gradient severe aortic valve stenosis), we recommend **calcium score CT of the aortic valve** as the next imaging modality (↑↑).
 - ↳ 1.2 In patients with suspected aortic valve stenosis where pulmonary oedema is suspected, we recommend **chest XR** as the next imaging modality (↑↑).

Aortic regurgitation

2. In patients with suspected aortic valve regurgitation, we recommend **TTE** as the initial imaging modality (↑↑).
 - ↳ 2.1 If further imaging is required due to poor acoustic windows or if information about ventricular size and function is required, we recommend **cardiac MRI** as the next imaging modality (↑↑) or **TEE** if the mechanism or severity of aortic valve regurgitation is unclear.
 - ↳ 2.2 If MRI is not tolerated, is unavailable, or is contraindicated, we recommend **cardiac CT** as an alternative imaging modality for evaluation of ventricular size and function (↑↑).
 - ↳ 2.3 In patients with suspected aortic valve regurgitation where pulmonary oedema is suspected, we recommend **chest XR** as the next imaging modality (↑↑).

Infective endocarditis—native valve

3. After completing TTE for aortic valve disease, we recommend **TEE** for suspected infective endocarditis, to further characterize stenosis severity or mechanism of regurgitation, and for ruling out aortic root abscess (↑↑).
 - ↳ 3.1 If there is concern for aortic root abscess and TEE is contraindicated, we recommend **cardiac CT** (↑↑).

Infective endocarditis—prosthetic valve

4. In patients with prosthetic valve, we recommend **TTE and TEE** for suspected infective endocarditis, to further characterize stenosis severity or mechanism of regurgitation, and for ruling out aortic root abscess (↑↑).
 - ↳ 4.1 If there is concern for aortic root abscess and TEE is contraindicated, we recommend **cardiac CT** (↑↑).
-

CV06B. Mitral valve^{9,11,12,14,18,20,54,61}

These recommendations are to guide diagnostic imaging of the mitral valve and does not include imaging to guide interventions.

Mitral stenosis

1. In patients with suspected mitral valve stenosis, we recommend **TTE** as the initial imaging modality (↑↑).
 - ↳ 1.1 If intervention is contemplated or required, we recommend **TEE** as the next imaging modality (↑↑).
2. In patients with suspected mitral valve stenosis where pulmonary oedema is suspected, we recommend **chest XR** as the next imaging modality (↑↑).

Mitral regurgitation

3. In patients with suspected mitral valve regurgitation, we recommend **TTE** as the initial imaging modality (↑↑).
 - ↳ 3.1 If the mechanism or severity is unclear on TTE, we recommend **TEE** as the next imaging modality (↑↑).
 - ↳ 3.2 If further imaging is required due to poor acoustic windows OR if information about ventricular size and function or confirmation of mitral regurgitation severity is required, we recommend **cardiac MRI** as the next imaging modality (↑↑).
 4. In patients with suspected mitral valve regurgitation where pulmonary oedema is suspected, we recommend **chest XR** as the next imaging modality (↑↑).
-

CV06C. Pulmonary valve^{9,11,12,14,18,20,54,61}

1. In patients with suspected pulmonary valve disease, we recommend **TTE** as the initial imaging modality (↑↑).
 - ↳ 1.1 If further imaging is required due to poor acoustic windows or if information about ventricular size and function is required (eg, tetralogy of Fallot), we recommend **cardiac MRI** as the next imaging modality (↑↑).
 - ↳ 1.2 If cardiac MRI is not tolerated, is unavailable, or is contraindicated, we recommend **cardiac CT** as an alternative imaging modality (↑↑).
-

(continued)

Table 3. (continued)**Clinical/Diagnostic Scenario and Recommendations**

2. After completing TTE for pulmonary valve disease, we suggest **TEE** for suspected infective endocarditis, to further characterize stenosis severity or mechanism of regurgitation, and for ruling out abscess (↑).
3. In patients with suspected pulmonary valve disease where supra and sub-valvular pathologies are possible based on TTE findings, we recommend **cardiac MRI** as the next imaging modality (↑↑).
 - ↳ **3.1** If cardiac MRI is not tolerated, is unavailable, or is contraindicated, we recommend **cardiac CT** as an alternative imaging modality (↑↑).

CV06D. Tricuspid valve^{9,11,12,14,18,20,54,61}

1. In patients with suspected tricuspid valve disease, we recommend **TTE** as the initial imaging modality (↑↑).
 - ↳ **1.1** If further imaging is required due to poor acoustic windows or if information about ventricular size and function is required, we recommend **cardiac MRI** as the next imaging modality (↑↑).
 - ↳ **1.2** If cardiac MRI is not tolerated, is unavailable, or is contraindicated, we recommend **cardiac CT** as an alternative imaging modality (↑↑).
2. After completing TTE for tricuspid valve disease, we suggest **TTE** for suspected infective endocarditis, to further characterize stenosis severity or mechanism of regurgitation, and for ruling out abscess (↑).

Note. Strength of recommendation: ↑↑=strong for; ↑=conditional for; ↓=conditional against; ↓↓=strong against. EP=Expert Panel; CAD=coronary artery disease; CCTA=coronary computed tomography angiography; CMR=cardiac magnetic resonance; CT=computed tomography; ECG=electrocardiogram; MR=magnetic resonance; MRI=magnetic resonance imaging; NM=nuclear medicine; PET=positron emission tomography; SPECT MPI=single-photon emission computed tomography myocardial perfusion imaging; TEE=transesophageal electrocardiography; TTE=transthoracic electrocardiography; XR=radiograph.

Table 4. Cardiomyopathy, Aorta, Venous Thrombosis, and Peripheral Vascular Disease Recommendations.**Clinical/Diagnostic Scenario and Recommendations****CV07. CARDIOMYOPATHY****CV07A. Cardiomyopathy: dilated**^{9,13,17,45,53}

1. In patients with suspected dilated cardiomyopathy, we recommend **TTE** as the initial imaging modality (↑↑).
 - ↳ **1.1** If ischaemic dilated cardiomyopathy is a possibility, we recommend **invasive catheter angiography** for further evaluation (↑↑).
 - ↳ **1.2** If invasive catheter angiography is unavailable, we recommend **CCTA** as an alternative (↑↑).
 - ↳ **1.3** If there is no significant obstructive coronary artery disease based on invasive catheter angiography or CCTA results and further imaging is required, we recommend **cardiac MRI** as the next imaging modality (↑↑).
 - ↳ **1.4** If information about ventricular size and function is required (and if ventricular size/function is unreliable by TTE) and cardiac MRI is not tolerated, is unavailable, or is contraindicated, we recommend **cardiac CT** (↑↑).
 - ↳ **1.5** If cardiac CT is not available, we suggest **NM (MUGA)** (↑).
NM (myocardial perfusion scan) may also be helpful to exclude significant ischaemia as a cause of dilated cardiomyopathy.

CV07B. Cardiomyopathy: hypertrophic^{9,13,17,31,32,45,53}

1. In patients with suspected hypertrophic cardiomyopathy, we recommend **TTE** as the initial imaging modality (↑↑).
 - ↳ **1.1** If further imaging is required[‡], we recommend **cardiac MRI** as the next imaging modality (↑↑).
 - ↳ **1.2** If information about ventricular size and function or maximum wall thickness is required AND cardiac MRI is not tolerated, is unavailable, or is contraindicated, we recommend **cardiac CT** (↑↑).
 - ↳ **1.3** To rule out obstructive coronary artery disease as a cause of symptoms, we recommend **invasive catheter angiography** (↑↑) in carefully selected patients.
 - ↳ **1.4** If invasive catheter angiography is unavailable, we recommend **CCTA** as an alternative (↑↑).

[‡]MRI can be helpful when echocardiography is inconclusive, when other diagnoses are possible (eg, amyloidosis, athlete's heart, storage disease, etc.), or when information about maximum wall thickness, ejection fraction, presence of apical aneurysm or extent of late gadolinium enhancement will influence decision to insert an implantable cardioverter-defibrillator (ICD).

(continued)

Table 4. (continued)

Clinical/Diagnostic Scenario and Recommendations

CV07C. Cardiomyopathy: restrictive^{9,13,17,36,40,45,49,52}

- I. In patients with suspected restrictive/infiltrative cardiomyopathy, we recommend **TTE** as the initial imaging modality (↑↑).
 - ↳ I.1 If further imaging is required, we recommend **cardiac MRI** as the next imaging modality (↑↑).
 - ↳ I.2 If information about ventricular size and function is required and cardiac MRI is not tolerated, is unavailable, or is contraindicated, we recommend **cardiac CT** (↑↑).
 - ↳ I.3 In patients with suspected cardiac sarcoidosis, we recommend **FDG-PET-CT** (↑↑).
 - ↳ I.4 In patients with suspected cardiac amyloidosis, if further imaging is required, we recommend **NM (pyrophosphate scan)** as the next imaging modality (↑↑).
-

CV07D. Cardiomyopathy: arrhythmogenic^{9,13,17,45}

- I. In patients with suspected arrhythmogenic cardiomyopathy, we recommend **TTE** as the initial imaging modality (↑↑).
 - ↳ I.1 If further imaging is required, we recommend **cardiac MRI** as the next imaging modality (↑↑).
 - ↳ I.2 If information about ventricular size and function is required and cardiac MRI is not tolerated, is unavailable, or is contraindicated, we recommend **cardiac CT** (↑↑).
 - ↳ I.3 If obstructive coronary artery disease needs to be ruled out as the cause for arrhythmia, we recommend **invasive catheter angiography** (↑↑).
 - ↳ I.4 If invasive catheter angiography is unavailable, we recommend **CCTA** as an alternative (↑↑).
-

CV08. Aorta

CV08A. Thoraco-abdominal aneurysm^{9,10,13,21,50,58,61,63}

- I. In patients with thoracic aortic aneurysm identified by TTE, we recommend **chest CTA** (preferably cardiac-gated) for baseline measurement and surveillance (↑↑).
In younger patients with thoraco-abdominal aortic aneurysm identified by TTE, MRA may be performed for baseline measurement and surveillance. Surgical consultation could be considered for aortas >4.5 cm in size.
2. In patients without underlying aortopathy with suspected abdominal aortic aneurysm (AAA) based on physical examination, we recommend **US** as the initial imaging modality (↑↑).
 - ↳ 2.1 If US demonstrates aortic diameter between 2.5 and 3.0 cm, we suggest re-evaluation with **US** after 10 years (↑↑).
 - ↳ 2.2 If US demonstrates aortic diameter between 3.0 and 3.9 cm, we recommend repeat **US** at 3-year intervals (↑↑).
 - ↳ 2.3 If US demonstrates aortic diameter between 4.0 and 4.9 cm, we recommend annual surveillance with **US or CT** (↑↑).
Surgical consultation could be considered for aortas >4.5 cm in size.

For detailed recommendations for patients with underlying aortopathies and sex specific recommendations, see ACC/AHA guideline.¹⁰

3. In patients with symptoms suspected to be related to thoraco-abdominal aneurysm, we recommend **CT with contrast** (↑↑).
-

CV08B. Vasculitis^{22,27,38,39,46-48}

- I. In patients with suspected vasculitis involving the aorta (ie, aortitis), we recommend **MRA** for baseline measurement and surveillance, especially in young patients (↑↑).
 - ↳ I.1 If MRA is not tolerated, is unavailable, or is contraindicated, we recommend **CTA** for baseline measurement and surveillance (↑↑).
 - ↳ I.2 If MRA or CTA results are inconclusive regarding disease activity, we suggest **FDG-PET-CT or MR-PET** (↑).
-

CV09. Venous thrombosis^{9,23,24,35,37,59-61,64}

- I. In patients with suspected deep vein thrombosis with low pre-test probability (as determined by a structured risk assessment tool) AND negative D-dimer, we recommend **no imaging** (↓↓↓).
 - ↳ I.1 If D-dimer is unavailable, we recommend **interim therapeutic anticoagulation and Doppler US** (↑↑).
 - ↳ I.2 If US is inconclusive or of poor quality and further imaging is required, we recommend **CTV or MRV** as the next imaging modality, with preference for MRV in younger patients (↑↑).
 2. In patients with suspected deep vein thrombosis based with intermediate/high pre-test probability (as determined by a structured risk assessment tool) and/or positive D-dimer, we recommend **Doppler US** as the initial imaging modality (↑↑).
 3. In patients with superficial venous thrombosis, we suggest **Doppler US** as the initial imaging modality (↑).
-

(continued)

Table 4. (continued)

Clinical/Diagnostic Scenario and Recommendations

CVI0. Peripheral vascular disease

CVI0A. Upper and lower extremity peripheral vascular disease^{9,22,25,28,61}

1. In patients with suspected upper or lower extremity peripheral vascular (arterial) disease based on symptoms or other clinical features and an abnormal ankle-brachial index (ABI < 0.9), we recommend **Doppler US** for further evaluation (↑↑).
 - ↳ 1.1 If further imaging is required, we recommend **CTA or MRA** as the next imaging modality (↑↑).
2. In patients with established upper or lower extremity peripheral vascular (arterial) disease with recurrent symptoms, we recommend **CTA or MRA** as the initial imaging modality (↑↑).

CVI0B. Vascular malformation^{26,62}

1. In patients with suspected vascular malformation, to further characterize and guide further management, we recommend **time-resolved MRA** as the initial imaging modality (↑↑).

In patients presenting with an extremity mass and suspected vascular malformation, Doppler US could be performed as the initial test.

 - ↳ 1.1 If MRA is not tolerated, is unavailable, or is contraindicated, we recommend **CTA** as an alternative (↑↑).
 - ↳ 1.2 To guide further management for high flow vascular malformations, we recommend **invasive catheter angiography** (↑↑).

CVI0C. Entrapment and compression syndrome²⁵

1. In patients with entrapment and compression syndromes involving the extremities where venous thrombosis is also of concern, we recommend **Doppler US** as the initial imaging modality (↑↑).
 - ↳ 1.1 If Doppler US is negative or indeterminate and additional imaging is required, we recommend **MRA** as the next imaging modality (↑↑).
 - ↳ 1.2 If MRA is not tolerated, is unavailable, or is contraindicated, we recommend or **CTA** as an alternative (↑↑).

Note. Strength of recommendation: ↑↑ = strong for; ↑ = conditional for; ↓ = conditional against; ↓↓ = strong against. EP = Expert Panel; CCTA = coronary computed tomography angiography; CT = computed tomography; CTA = computed tomography angiography; CTV = computed tomography venography; FDG-PET-CT = fluorodeoxyglucose-positron emission tomography computed tomography; MR-PET = magnetic resonance-positron emission tomography; MRA = magnetic resonance angiography; MRI = magnetic resonance imaging; MRV = magnetic resonance venography; MUGA = multigated acquisition scan; NM = nuclear medicine; TTE = transthoracic electrocardiography; US = ultrasound.

Acknowledgments

We would like to thank: Becky Skidmore for creating the search strategies for the systematic scoping review, and the following individuals on the Diagnostic Imaging Referral Guidelines Working Group and external stakeholders for providing feedback on the guideline (listed alphabetically): Steve Burrell, Ryan Margau (WG co-chair), Paul Pageau (WG co-chair), Erin Sarrazin, Charlotte Yong-Hing, and Kaitlin Zaki-Metias.

Declaration of Conflicting Interests


The author(s) declared no potential conflicts of interest with respect to the research, authorship, and/or publication of this article.


Funding

The author(s) disclosed receipt of the following financial support for the research, authorship, and/or publication of this article: This work was supported by the Canadian Medical Association.

ORCID iDs

Candace Hamel  <https://orcid.org/0000-0002-5871-2137>

Alan Michaud  <https://orcid.org/0000-0001-9217-7361>

Elsie T. Nguyen  <https://orcid.org/0000-0002-6074-2968>

Supplemental Material

Supplemental material for this article is available online.

References

1. Hamel C, Margau R, Pageau P, et al. Canadian Association of Radiologists diagnostic imaging referral guidelines: a guideline development protocol. *CMAJ Open*. 2023;11(2):E248-E254. doi:10.9778/cmajo.20220098
2. Hamel C, Venturi M, Margau R, Pageau P. Canadian Association of Radiologists diagnostic imaging referral guidelines. *Can Assoc Radiol J*. Published online April 4, 2023. doi:10.1177/08465371231169746
3. Peters M, Godfrey C, McInerney P, Munn Z, Tricco A, Khalil H. Chapter 11. Scoping reviews. In: Aromataris E, Munn Z, eds. *JBIM Manual for Evidence Synthesis*. The Joanna Briggs Institute; 2020. Accessed February 24, 2021. <https://doi.org/10.46658/JBIMES-20-12>
4. Higgins J, Thomas J, Chandler J, et al. *Cochrane Handbook for Systematic Reviews of Interventions Version 6.2 (Updated February 2021)*; 2021. www.training.cochrane.org/handbook
5. Garritty C, Gartlehner G, Nussbaumer-Streit B, et al. Cochrane Rapid Reviews Methods Group offers evidence-informed guidance to conduct rapid reviews. *J Clin Epidemiol*. 2021;130:13-22. doi:10.1016/j.jclinepi.2020.10.007

6. Andrews J, Guyatt G, Oxman AD, et al. GRADE guidelines: 14. Going from evidence to recommendations: the significance and presentation of recommendations. *J Clin Epidemiol*. 2013;66(7):719-725. doi:10.1016/j.jclinepi.2012.03.013
7. Andrews JC, Schünemann HJ, Oxman AD, et al. GRADE guidelines: 15. Going from evidence to recommendation-determinants of a recommendation's direction and strength. *J Clin Epidemiol*. 2013;66(7):726-735. doi:10.1016/j.jclinepi.2013.02.003
8. AGREE Next Steps Consortium (2017). The AGREE II Instrument [Electronic Version]. Published online 2017. Accessed March 3, 2022. <https://www.agreetrust.org/wp-content/uploads/2017/12/AGREE-II-Users-Manual-and-23-item-Instrument-2009-Update-2017.pdf>
9. Canadian Association of Radiologists. *2012 CAR Diagnostic Imaging Referral Guidelines*. Canadian Association of Radiologists; 2012. Accessed July 5, 2021. <https://car.ca/patient-care/referral-guidelines/>
10. Isselbacher EM, Preventza O, Hamilton Black J, et al. 2022 ACC/AHA guideline for the diagnosis and management of aortic disease: a report of the American Heart Association/American College of Cardiology Joint Committee on Clinical Practice Guidelines. *Circulation*. 2022;146(24):e334-e482. doi:10.1161/CIR.0000000000001106
11. Otto CM, Nishimura RA, Bonow RO, et al. 2020 ACC/AHA guideline for the management of patients with valvular heart disease: a report of the American College of Cardiology/American Heart Association Joint Committee on Clinical Practice Guidelines. *Circulation*. 2021;143(5):e72-e227. doi:10.1161/CIR.0000000000000923
12. Otto CM, Nishimura RA, Bonow RO, et al. 2020 ACC/AHA guideline for the management of patients with valvular heart disease: executive summary: a report of the American College of Cardiology/American Heart Association Joint Committee on Clinical Practice Guidelines. *Circulation*. 2021;143(5):e35-e71. doi:10.1161/CIR.0000000000000932
13. Doherty JU, Kort S, Mehran R, et al. ACC/AATS/AHA/ASE/ASNC/HRS/SCAI/SCCT/SCMR/STS 2019 appropriate use criteria for multimodality imaging in the assessment of cardiac structure and function in nonvalvular heart disease: a report of the American College of Cardiology Appropriate Use Criteria Task Force, American Association for Thoracic Surgery, American Heart Association, American Society of Echocardiography, American Society of Nuclear Cardiology, Heart Rhythm Society, Society for Cardiovascular Angiography and Interventions, Society of Cardiovascular Computed Tomography, Society for Cardiovascular Magnetic Resonance, and the Society of Thoracic Surgeons. *J Thorac Cardiovasc Surg*. 2019;157(4):e153-e182. doi:10.1016/j.jtcvs.2018.12.061
14. Doherty JU, Kort S, Mehran R, et al. ACC/AATS/AHA/ASE/ASNC/HRS/SCAI/SCCT/SCMR/STS 2017 appropriate use criteria for multimodality imaging in valvular heart disease: a report of the American College of Cardiology Appropriate Use Criteria Task Force, American Association for Thoracic Surgery, American Heart Association, American Society of Echocardiography, American Society of Nuclear Cardiology, Heart Rhythm Society, Society for Cardiovascular Angiography and Interventions, Society of Cardiovascular Computed Tomography, Society for Cardiovascular Magnetic Resonance, and Society of Thoracic Surgeons. *J Am Soc Echocardiogr*. 2018;31(4):381-404. doi:10.1016/j.echo.2017.08.012
15. Expert Panel on Cardiac Imaging, Kicska GA, Hurwitz Koweek LM, et al. ACR Appropriateness Criteria® suspected acute aortic syndrome. *J Am Coll Radiol*. 2021;18(11S):S474-S481. doi:10.1016/j.jacr.2021.09.004
16. Expert Panel on Cardiac Imaging, Kirsch J, Wu CC, et al. ACR Appropriateness Criteria® suspected pulmonary embolism: 2022 update. *J Am Coll Radiol*. 2022;19(11S):S488-S501. doi:10.1016/j.jacr.2022.09.014
17. Expert Panel on Cardiac Imaging, Rajiah P, Kirsch J, et al. ACR Appropriateness Criteria® nonischemic myocardial disease with clinical manifestations (ischemic cardiomyopathy already excluded). *J Am Coll Radiol*. 2021;18(5S):S83-S105. doi:10.1016/j.jacr.2021.01.019
18. Expert Panel on Cardiac Imaging, Bolen MA, Bin Saeedan MN, et al. ACR Appropriateness Criteria® dyspnea-suspected cardiac origin (ischemia already excluded): 2021 update. *J Am Coll Radiol*. 2022;19(5S):S37-S52. doi:10.1016/j.jacr.2022.02.014
19. Expert Panel on Cardiac Imaging, Litmanovich D, Hurwitz Koweek LM, et al. ACR Appropriateness Criteria® chronic chest pain-high probability of coronary artery disease: 2021 update. *J Am Coll Radiol*. 2022;19(5S):S1-S18. doi:10.1016/j.jacr.2022.02.021
20. Expert Panel on Cardiac Imaging, Malik SB, Hsu JY, et al. ACR Appropriateness Criteria® infective endocarditis. *J Am Coll Radiol*. 2021;18(5S):S52-S61. doi:10.1016/j.jacr.2021.01.010
21. Expert Panel on Vascular Imaging, Bennett SJ, Dill KE, et al. ACR Appropriateness Criteria® suspected thoracic aortic aneurysm. *J Am Coll Radiol*. 2018;15(5S):S208-S214. doi:10.1016/j.jacr.2018.03.031
22. Expert Panel on Vascular Imaging, Aghayev A, Steigner ML, et al. ACR Appropriateness Criteria® noncerebral vasculitis. *J Am Coll Radiol*. 2021;18(11S):S380-S393. doi:10.1016/j.jacr.2021.08.005
23. Expert Panel on Vascular Imaging, Desjardins B, Hanley M, et al. ACR Appropriateness Criteria® suspected upper extremity deep vein thrombosis. *J Am Coll Radiol*. 2020;17(5S):S315-S322. doi:10.1016/j.jacr.2020.01.020
24. Expert Panel on Vascular Imaging, Hanley M, Steigner ML, et al. ACR Appropriateness Criteria® suspected lower extremity deep vein thrombosis. *J Am Coll Radiol*. 2018;15(11S):S413-S417. doi:10.1016/j.jacr.2018.09.028
25. Expert Panels on Vascular Imaging, Francois CJ, Skulborstad EP, et al. ACR Appropriateness Criteria® non-atherosclerotic peripheral arterial disease. *J Am Coll Radiol*. 2019;16(5S):S174-S183. doi:10.1016/j.jacr.2019.02.026
26. Expert Panel on Vascular Imaging, Obara P, McCool J, et al. ACR Appropriateness Criteria® clinically suspected vascular malformation of the extremities. *J Am Coll Radiol*. 2019;16(11S):S340-S347. doi:10.1016/j.jacr.2019.05.013
27. Maz M, Chung SA, Abril A, et al. 2021 American College of Rheumatology/Vasculitis Foundation guideline for the management of giant cell arteritis and Takayasu arteritis. *Arthritis Rheumatol*. 2021;73(8):1349-1365. doi:10.1002/art.41774
28. Chung SA, Gorelik M, Langford CA, et al. 2021 American College of Rheumatology/Vasculitis Foundation guideline for the management of polyarteritis nodosa. *Arthritis Rheumatol*. 2021;73(8):1384-1393. doi:10.1002/art.41776
29. Gulati M, Levy PD, Mukherjee D, et al. 2021 AHA/ACC/ASE/CHEST/SAEM/SCCT/SCMR guideline for the evaluation and diagnosis of chest pain: a report of the American College of Cardiology/American Heart Association Joint Committee on Clinical Practice Guidelines. *J Am Coll Cardiol*. 2021;78(22):e187-e285. doi:10.1016/j.jacc.2021.07.053

30. Gulati M, Levy PD, Mukherjee D, et al. 2021 AHA/ACC/AASE/CHEST/SAEM/SCCT/SCMR guideline for the evaluation and diagnosis of chest pain: executive summary: a report of the American College of Cardiology/American Heart Association Joint Committee on Clinical Practice Guidelines. *Circulation*. 2021;144(22):e368-e454. doi:10.1161/CIR.0000000000001029
31. Ommen SR, Mital S, Burke MA, et al. 2020 AHA/ACC guideline for the diagnosis and treatment of patients with hypertrophic cardiomyopathy: a report of the American College of Cardiology/American Heart Association Joint Committee on Clinical Practice Guidelines. *Circulation*. 2020;142(25):e558-e631. doi:10.1161/CIR.0000000000000937
32. Ommen SR, Mital S, Burke MA, et al. 2020 AHA/ACC guideline for the diagnosis and treatment of patients with hypertrophic cardiomyopathy: executive summary: a report of the American College of Cardiology/American Heart Association Joint Committee on Clinical Practice Guidelines. *J Am Coll Cardiol*. 2020;76(25):3022-3055. doi:10.1016/j.jacc.2020.08.044
33. Heidenreich PA, Bozkurt B, Aguilar D, et al. 2022 AHA/ACC/HFSA guideline for the management of heart failure: a report of the American College of Cardiology/American Heart Association Joint Committee on Clinical Practice Guidelines. *Circulation*. 2022;145(18):e895-e1032. doi:10.1161/CIR.0000000000001063
34. Heidenreich PA, Bozkurt B, Aguilar D, et al. 2022 AHA/ACC/HFSA guideline for the management of heart failure: executive summary: a report of the American College of Cardiology/American Heart Association Joint Committee on Clinical Practice Guidelines. *Circulation*. 2022;145(18):e876-e894. doi:10.1161/CIR.0000000000001062
35. Lim W, Le Gal G, Bates SM, et al. American Society of Hematology 2018 guidelines for management of venous thromboembolism: diagnosis of venous thromboembolism. *Blood Adv*. 2018;2(22):3226-3256. doi:10.1182/bloodadvances.2018024828
36. Crouser ED, Maier LA, Wilson KC, et al. Diagnosis and detection of sarcoidosis. An official American Thoracic Society clinical practice guideline. *Am J Respir Crit Care Med*. 2020;201(8):e26-e51. doi:10.1164/rccm.202002-0251ST
37. de Almeida MJ, Guillaumon AT, Miquelin D, et al. Guidelines for superficial venous thrombosis. *J Vasc Bras*. 2019;18:e20180105. doi:10.1590/1677-5449.180105
38. Mackie SL, Dejaco C, Appenzeller S, et al. British Society for Rheumatology guideline on diagnosis and treatment of giant cell arteritis. *Rheumatology (Oxford)*. 2020;59(3):e1-e23. doi:10.1093/rheumatology/kez672
39. Mackie SL, Dejaco C, Appenzeller S, et al. British Society for Rheumatology guideline on diagnosis and treatment of giant cell arteritis: executive summary. *Rheumatology (Oxford)*. 2020;59(3):487-494. doi:10.1093/rheumatology/kez664
40. Fine NM, Davis MK, Anderson K, et al. Canadian Cardiovascular Society/Canadian Heart Failure Society joint position statement on the evaluation and management of patients with cardiac amyloidosis. *Can J Cardiol*. 2020;36(3):322-334. doi:10.1016/j.cjca.2019.12.034
41. Collet JP, Thiele H, Barbato E, et al. 2020 ESC Guidelines for the management of acute coronary syndromes in patients presenting without persistent ST-segment elevation. *Eur Heart J*. 2021;42(14):1289-1367. doi:10.1093/eurheartj/ehaa575
42. Konstantinides SV, Meyer G, Becattini C, et al. 2019 ESC Guidelines for the diagnosis and management of acute pulmonary embolism developed in collaboration with the European Respiratory Society (ERS). *Eur Heart J*. 2020;41(4):543-603. doi:10.1093/eurheartj/ehz405
43. McDonagh TA, Metra M, Adamo M, et al. 2021 ESC Guidelines for the diagnosis and treatment of acute and chronic heart failure. *Eur Heart J*. 2021;42(36):3599-3726. doi:10.1093/eurheartj/ehab368
44. Knuuti J, Wijns W, Saraste A, et al. 2019 ESC Guidelines for the diagnosis and management of chronic coronary syndromes. *Eur Heart J*. 2020;41(3):407-477. doi:10.1093/eurheartj/ehz425
45. Zeppenfeld K, Tfelt-Hansen J, de Riva M, et al. 2022 ESC Guidelines for the management of patients with ventricular arrhythmias and the prevention of sudden cardiac death. *Eur Heart J*. 2022;43(40):3997-4126. doi:10.1093/eurheartj/ehac262
46. Hellmich B, Agueda A, Monti S, et al. 2018 Update of the EULAR recommendations for the management of large vessel vasculitis. *Ann Rheum Dis*. 2020;79(1):19-30. doi:10.1136/annrheumdis-2019-215672
47. Dejaco C, Ramiro S, Duftner C, et al. EULAR recommendations for the use of imaging in large vessel vasculitis in clinical practice. *Ann Rheum Dis*. 2018;77(5):636-643. doi:10.1136/annrheumdis-2017-212649
48. Bardi M, Diamantopoulos AP. EULAR recommendations for the use of imaging in large vessel vasculitis in clinical practice summary. *Radiol Med*. 2019;124(10):965-972. doi:10.1007/s11547-019-01058-0
49. Yilmaz A, Bauersachs J, Bengel F, et al. Diagnosis and treatment of cardiac amyloidosis: position statement of the German Cardiac Society (DGK). *Clin Res Cardiol*. 2021;110(4):479-506. doi:10.1007/s00392-020-01799-3
50. Pratesi C, Esposito D, Apostolou D, et al. Guidelines on the management of abdominal aortic aneurysms: updates from the Italian Society of Vascular and Endovascular Surgery (SICVE). *J Cardiovasc Surg (Torino)*. 2022;63(3):328-352. doi:10.23736/S0021-9509.22.12330-X
51. Yamagishi M, Tamaki N, Akasaka T, et al. JCS 2018 guideline on diagnosis of chronic coronary heart diseases. *Circ J*. 2021;85(4):402-572. doi:10.1253/circj.CJ-19-1131
52. Kitaoka H, Izumi C, Izumiya Y, et al. JCS 2020 guideline on diagnosis and treatment of cardiac amyloidosis. *Circ J*. 2020;84(9):1610-1671. doi:10.1253/circj.CJ-20-0110
53. Kitaoka H, Tsutsui H, Kubo T, et al. JCS/JHFS 2018 guideline on the diagnosis and treatment of cardiomyopathies. *Circ J*. 2021;85(9):1590-1689. doi:10.1253/circj.CJ-20-0910
54. Izumi C, Eishi K, Ashihara K, et al. JCS/JSCS/JATS/JSVS 2020 guidelines on the management of valvular heart disease. *Circ J*. 2020;84(11):2037-2119. doi:10.1253/circj.CJ-20-0135
55. NHFA CSANZ Heart Failure Guidelines Working Group, Atherton JJ, Sindone A, et al. National Heart Foundation of Australia and Cardiac Society of Australia and New Zealand: guidelines for the prevention, detection, and management of heart failure in Australia 2018. *Heart Lung Circ*. 2018;27(10):1123-1208. doi:10.1016/j.hlc.2018.06.1042
56. NICE Guideline. *NICE (NG185): Acute Coronary Syndromes*. National Institute for Health and Care Excellence (NICE); 2020. Accessed June 27, 2023. www.nice.org.uk/guidance/ng185
57. Corbett SJ, Ftouh S, Lewis S, Lovibond K; Guideline Committee. Acute coronary syndromes: summary of updated NICE guidance. *BMJ*. 2021;372:m4760. doi:10.1136/bmj.m4760
58. NICE Guideline. *NICE (NG156): Abdominal Aortic Aneurysm: Diagnosis and Management*. National Institute for Health and

- Care Excellence (NICE); 2020. Accessed June 27, 2023. www.nice.org.uk/guidance/ng156
59. NICE Guideline. *NICE (NG158): Venous Thromboembolic Diseases: Diagnosis, Management and Thrombophilia Testing*. National Institute for Health and Care Excellence (NICE); 2020. Accessed June 27, 2023. www.nice.org.uk/guidance/ng158
60. Chaplin S. NICE on the management of venous thromboembolic diseases. *Prescriber - Wiley Online Library*. Published online 2020. Accessed July 10, 2023. <https://wchh.onlinelibrary.wiley.com/doi/full/10.1002/psb.1880>
61. The Royal College of Radiologists. *RCR iRefer Guidelines: Making the Best Use of Clinical Radiology*. The Royal College of Radiologists; 2017.
62. Stillo F, Mattassi R, Diociaiuti A, et al. Guidelines for vascular anomalies by the Italian Society for the study of Vascular Anomalies (SISAV). *Int Angiol*. 2022;41(2 Suppl 1):1-130. doi:10.23736/S0392-9590.22.04902-1
63. Chaer RA, Abularrage CJ, Coleman DM, et al. The Society for Vascular Surgery clinical practice guidelines on the management of visceral aneurysms. *J Vasc Surg*. 2020;72(1S):3S-39S. doi:10.1016/j.jvs.2020.01.039
64. Tran HA, Gibbs H, Merriman E, et al. New guidelines from the Thrombosis and Haemostasis Society of Australia and New Zealand for the diagnosis and management of venous thromboembolism. *Med J Aust*. 2019;210(5):227-235. doi:10.5694/mja2.50004
65. Jabehdar Maralani P, Kapadia A, Liu G, et al. Canadian Association of Radiologists recommendations for the safe use of MRI during pregnancy. *Can Assoc Radiol J*. 2022;73(1):56-67. doi:10.1177/08465371211015657
66. Hamel C, Avard B, Belanger C, et al. Canadian Association of Radiologists thoracic imaging referral guideline. *Can Assoc Radiol J*. Published online December 15, 2023. doi:10.1177/08465371231214699